


7 Day Ambulatory ECG Holter Report



Red  Serious ECG abnormality observed. Suggest urgent discussion with a cardiologist and/or referral to hospital. Reason For Rating: Complete heart block throughout - asymptomatic, average rate 35bpm.

Patient Number: Test Date: 25/01/2020 23:21:14
Patient Name: Training Three Requesting Site: Demo Practice
Patient D.O.B.: 30/04/1979 (40 Years) Requesting Clinician: --

Metrics

Duration of Recording

Total monitoring time: 7d 43s
Total time analysed: 6d 23h 44m 31s
Noise burden: 0.16 %

Heart Rate

Max: 28/01/2020 08:55:17 43 bpm
Min: 29/01/2020 04:29:24 31 bpm
Average: 35 bpm

Premature Supraventricular Complexes

Total PSVC beats: 0
No. of couplets: 0

Premature Ventricular Complexes

Total PVC beats: 5
No. of morphologies: 0
No. of couplets: 0
Total Bigeminy beats: 0
Total Trigeminy beats: 0

Episodes

Pauses

No. of pauses: 0
Longest RR interval: --

Atrioventricular block

Type: Complete AV block (3rd degree) (100%)

Atrial Fibrillation / Flutter

Burden: 0%
Longest episode: --
Max HR: --

Ventricular Tachycardia

No. of episodes: 0
Longest episode: --

Other Supraventricular Tachycardia

No. of episodes: 0
Longest episode: --

Patient Notified Events

Count: 0

Cardiac Physiologist Report

7d Holter recording.

Complete heart block (3rd degree AV block) noted throughout recording period with very limited heart rate profile. Longest RR interval 1990ms. QRS duration appears within normal limits throughout 106-119ms.

Change in P-wave morphology seen when P-wave rate increases - possible intermittent ectopic atrial rhythm at lower rates. 2 atrial foci noted (bifid appearance noted at P-wave rates <75bpm).

PP intervals ranging from 858ms/70bpm to 508ms/118bpm.

Minimum rate 31 bpm on Day 5 / 04:29:24, maximum rate 43 bpm on Day 4 / 08:55:17, average rate 35 bpm.

Limited variation in heart rate seen across the recording period.

2 unifocal PVCs seen in isolation. One slow, irregular RR interval broad complex triplet noted.

No diary returned. No symptoms reported.

If you require clinical advice and guidance in relation to this report, please use our Consultant Cardiologist E-Consultation Tool.

Reporter: Stephanie Barrett
Physiologist
18/03/2021 13:45:29

0345 5212992
cardiology@ecg-od.com



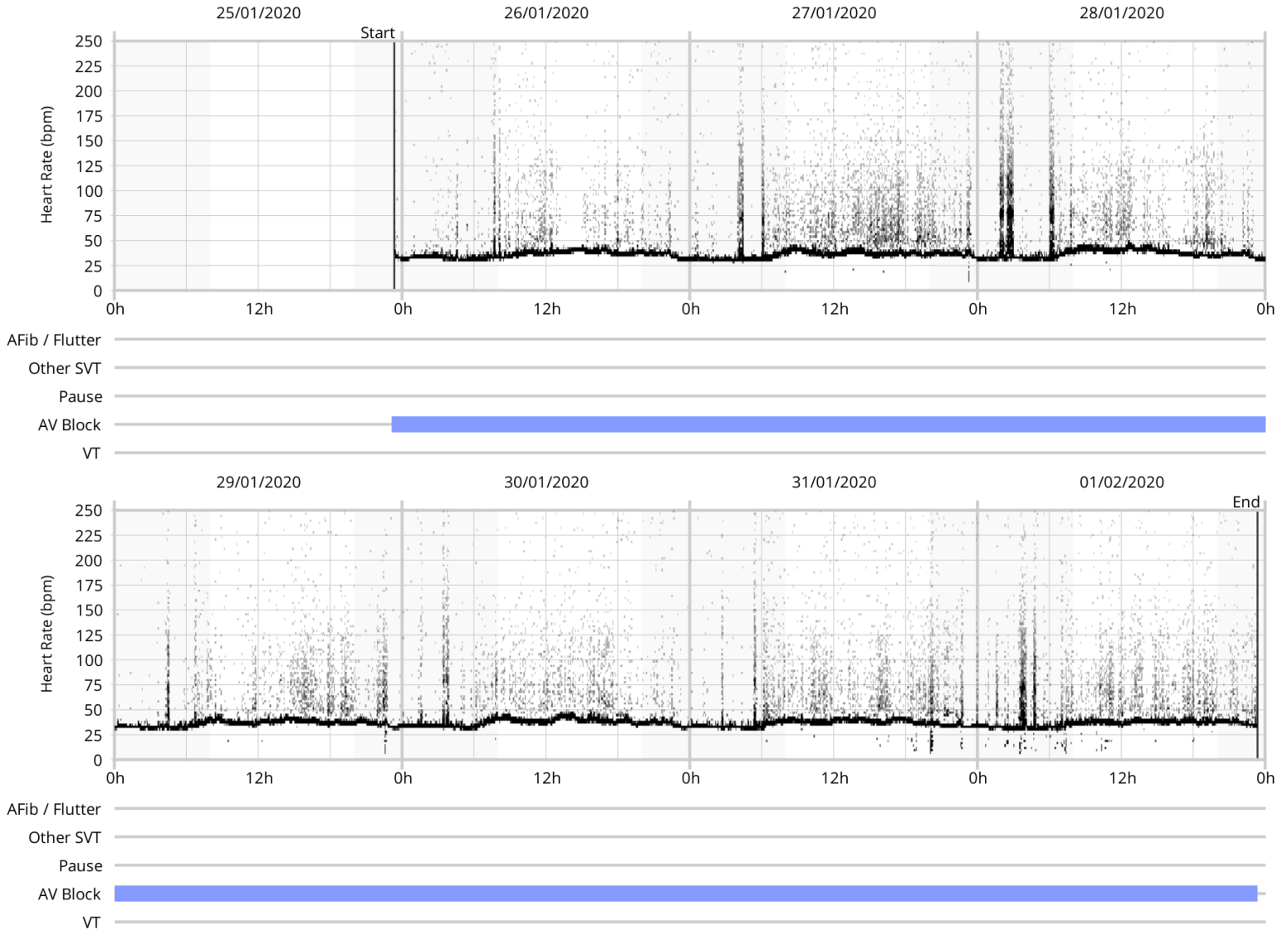
ECG On-Demand
Unit 23, 1912 Mill, Sunny Bank Mills
83-85 Town Street, Farsley
West Yorkshire
LS28 5UJ

<https://www.ecg-od.com>

Heart Rate Trend

Min HR Max HR Avg HR Bradycardia Episode Count Tachycardia Episode Count
31bpm **43bpm** **35bpm** **335 (97.45%)** --

⚠ Patient Event Ⓜ Physician Notification ■ AFib / Flutter



Atrial Fibrillation / Flutter Hourly Burden

No AFib found in the study

PSVC Hourly Burden

No PSVCs found in the study

PVC Hourly Burden

No PVCs found in the study

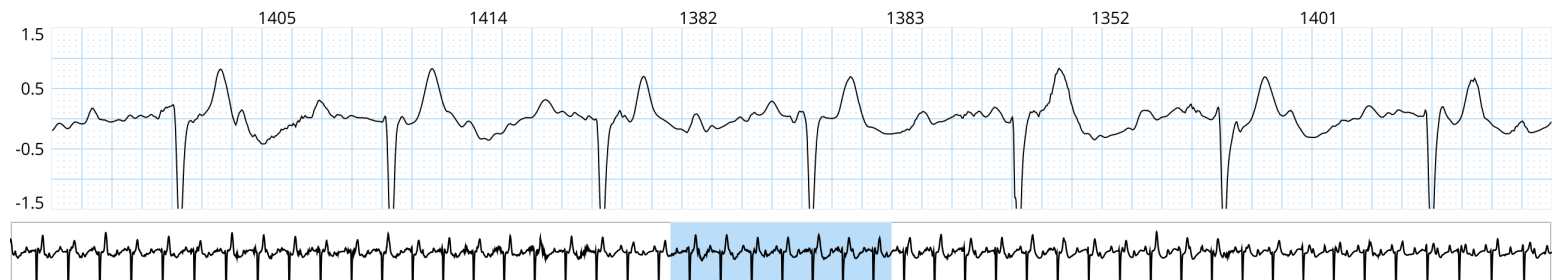
Strip Index

ID	Date & Time	Category	HR	Physician Notification	Association	Comments	Page
1	28/01/2020 08:55:17	Max HR	43bpm	--	--	Maximum heart rate - PP interval 508ms/118bpm	page 3
2	29/01/2020 04:29:24	Min HR	31bpm	--	--	Minimum heart rate - PP interval 828ms/72bpm	page 4
3	25/01/2020 23:21:14	AV Block	37bpm	--	--		page 4
4	27/01/2020 22:44:23	AV Block	34bpm	--	--		page 4
5	28/01/2020 23:02:50	AV Block	32bpm	--	--		page 4
6	31/01/2020 13:05:53	AV Block	38bpm	--	--		page 5
7	26/01/2020 04:47:07	Manually Added	29bpm	--	--	QRS duration 119ms	page 5
8	27/01/2020 19:59:42	Manually Added	34bpm	--	--	Increase in SA node rate: PP interval - 750ms/80bpm to 664ms/90bpm	page 5
9	28/01/2020 01:05:41	Manually Added	31bpm	--	--	Change in P-wave morphology noted with increase in P-wave rate	page 6
10	28/01/2020 01:10:25	Manually Added	31bpm	--	--	Change in P-wave morphology noted with increase in P-wave rate	page 7
11	30/01/2020 08:02:16	Manually Added	39bpm	--	--	PP interval 621ms/97bpm. RR interval 1523ms/39bpm	page 7
12	30/01/2020 08:57:29	Manually Added	41bpm	--	--	PP interval 523ms/115bpm. QRS duration 106ms	page 8
13	30/01/2020 17:54:55	Manually Added	44bpm	--	--	Irregular broad complex triplet	page 8
14	31/01/2020 22:45:24	Manually Added	32bpm	--	--	PP interval 859ms/70bpm. QRS duration 115ms	page 8
15	01/02/2020 14:50:15	Manually Added	53bpm	--	--	Isolated PVCs	page 8

Max HR

1. 28/01/2020 08:55:17

HR: 43bpm

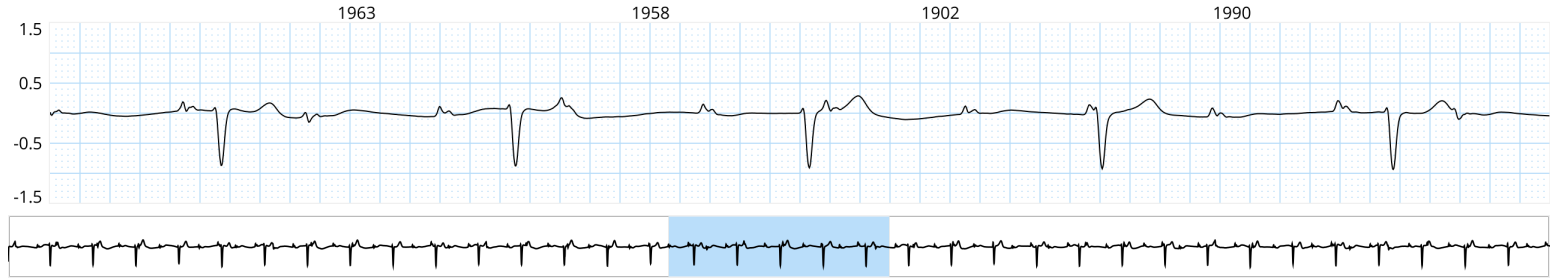


Comment: Maximum heart rate - PP interval 508ms/118bpm

Min HR

2. 29/01/2020 04:29:24

HR: 31bpm



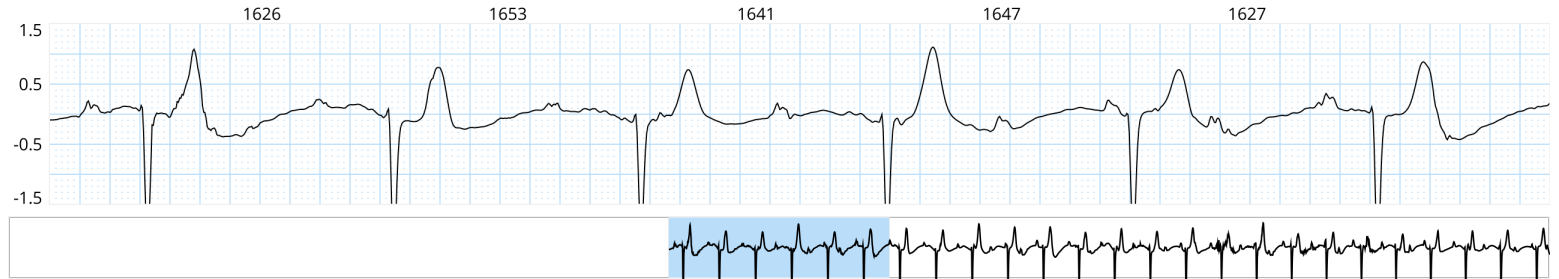
Comment: Minimum heart rate - PP interval 828ms/72bpm

AV Block

3. 25/01/2020 23:21:14

Type: Complete AV block (3rd degree)

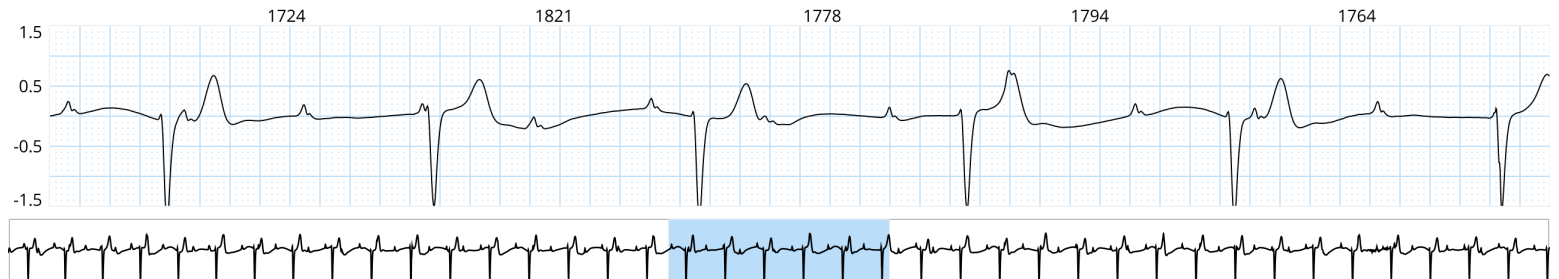
HR: 37bpm



4. 27/01/2020 22:44:23

Type: --

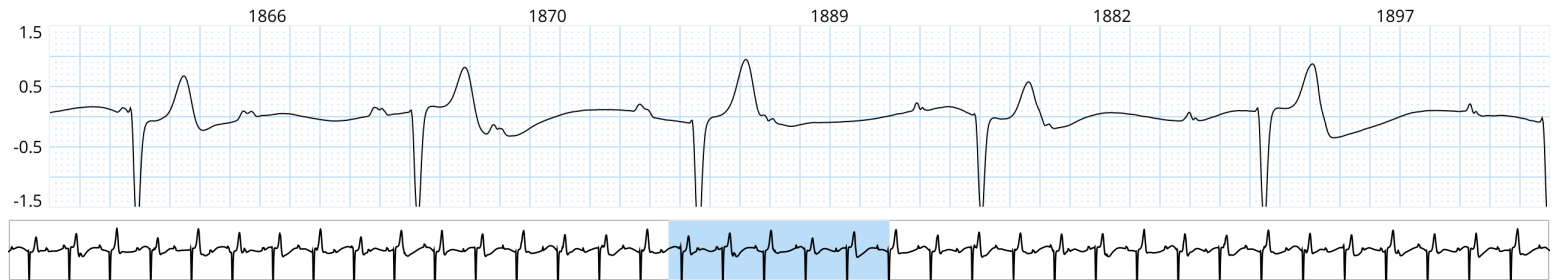
HR: 34bpm



5. 28/01/2020 23:02:50

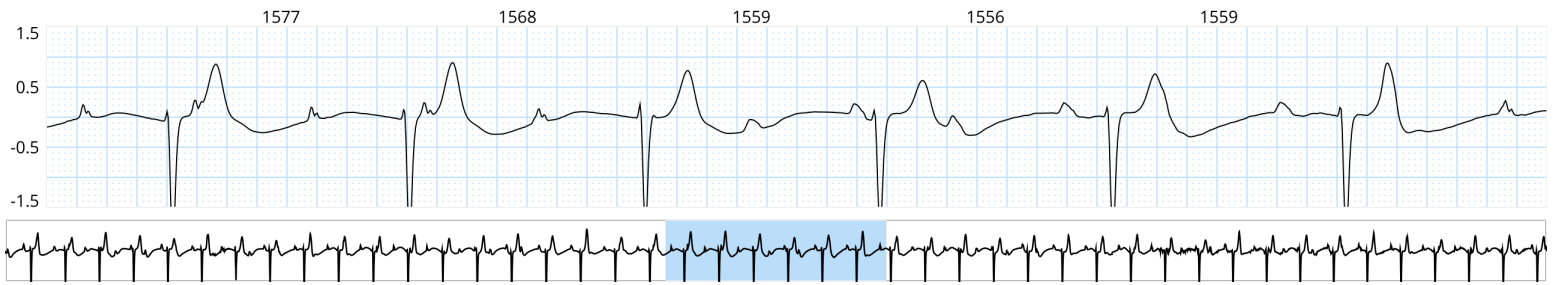
Type: --

HR: 32bpm



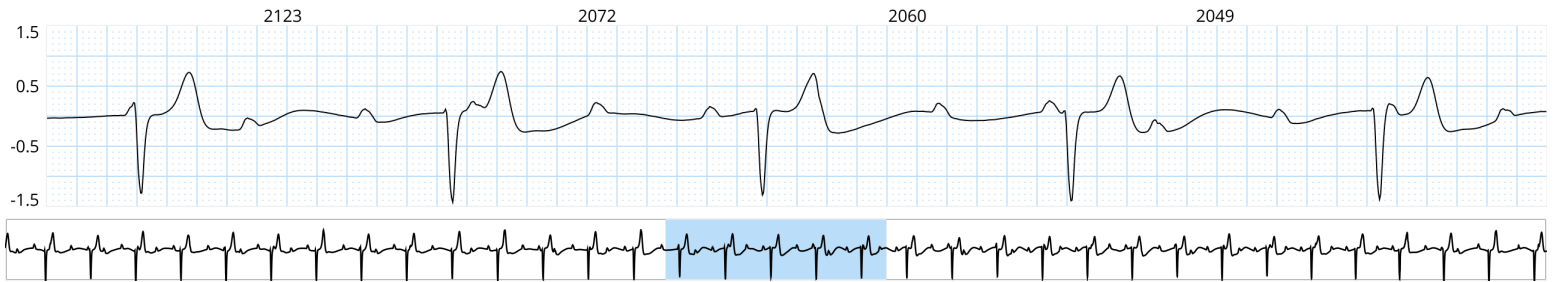
6. 31/01/2020 13:05:53

Type: --
HR: 38bpm



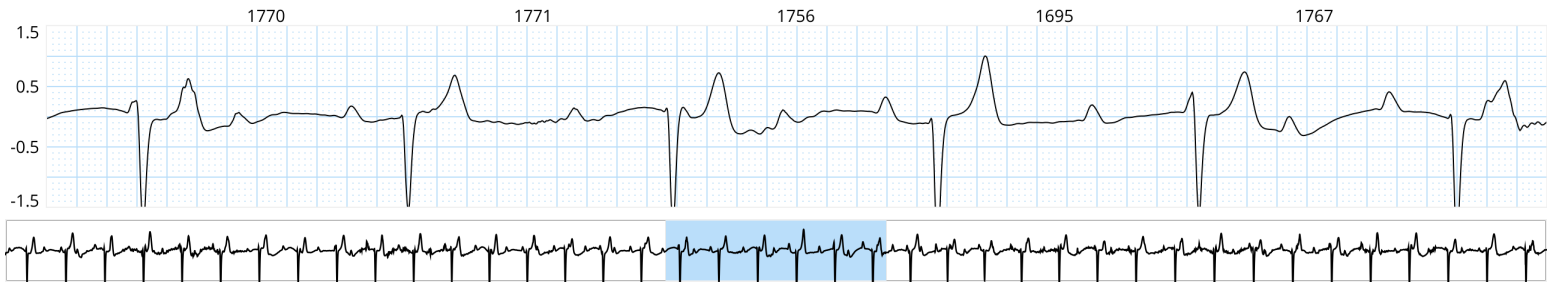
Manually Added

7. 26/01/2020 04:47:07

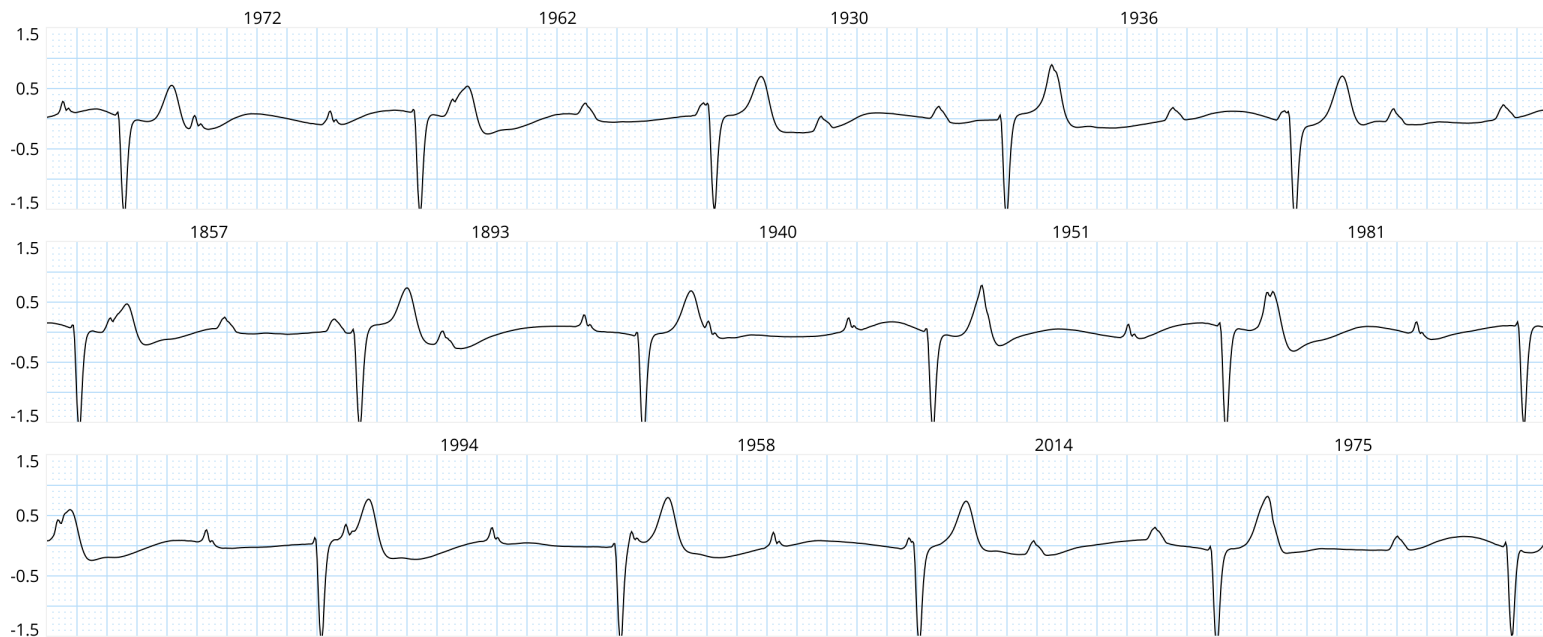


Comment: QRS duration 119ms

8. 27/01/2020 19:59:42

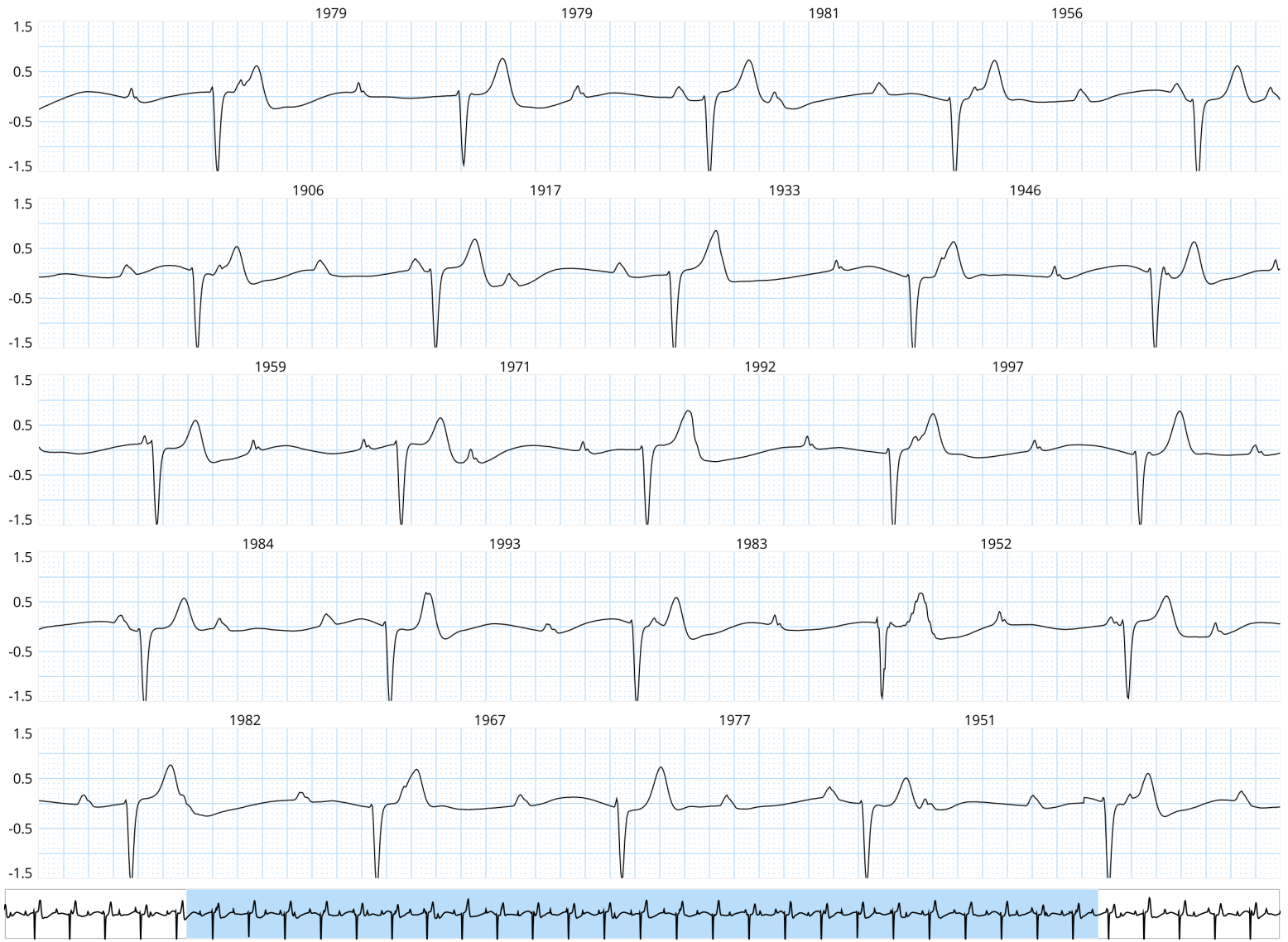


Comment: Increase in SA node rate: PP interval - 750ms/80bpm to 664ms/90bpm



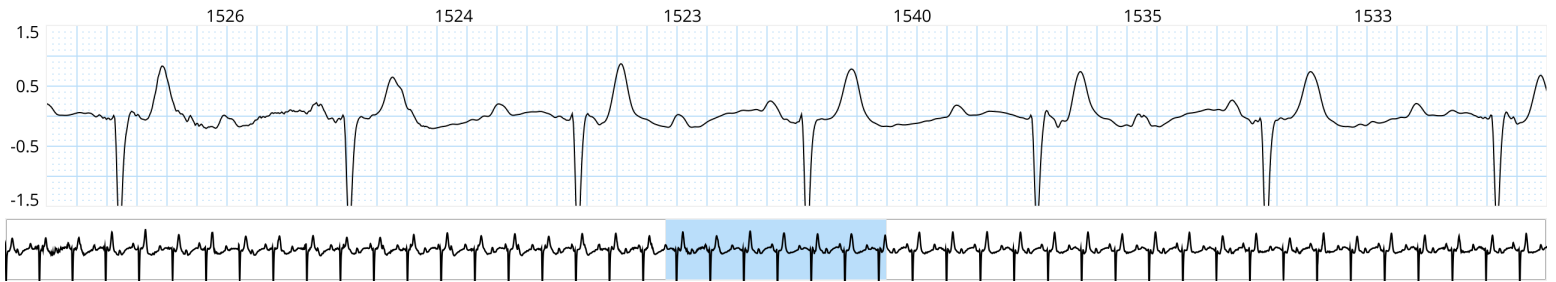
Comment: Change in P-wave morphology noted with increase in P-wave rate

10. 28/01/2020 01:10:25



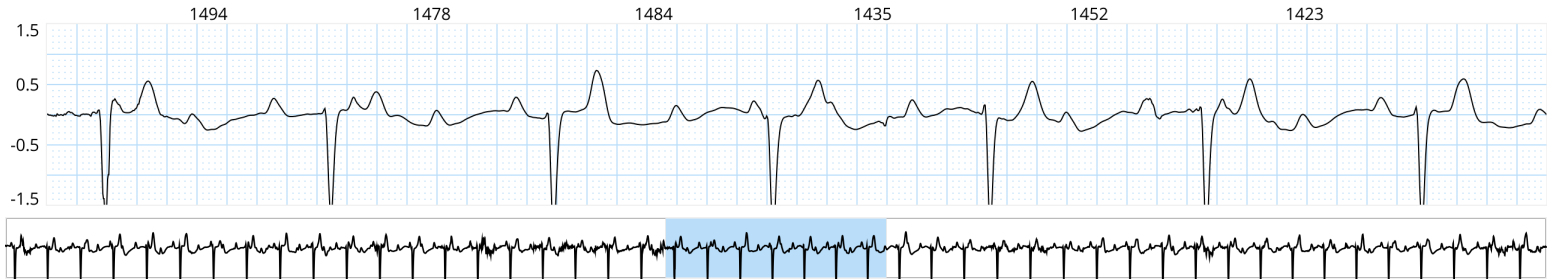
Comment: Change in P-wave morphology noted with increase in P-wave rate

11. 30/01/2020 08:02:16



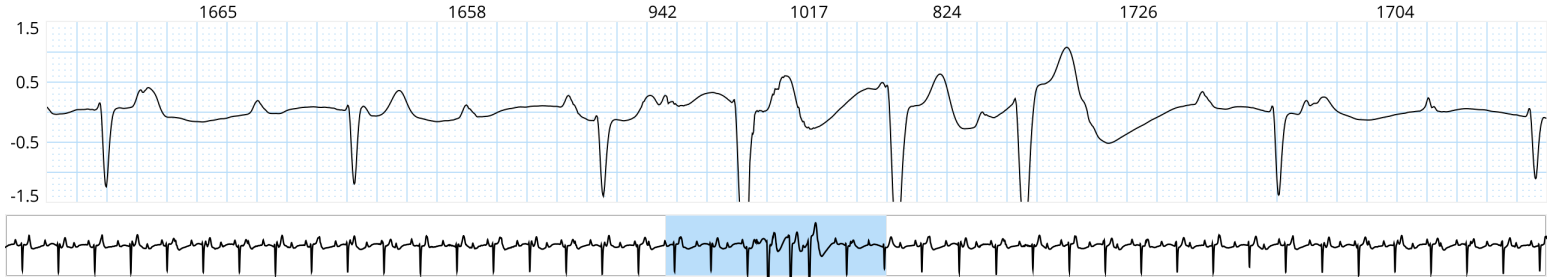
Comment: PP interval 621ms/97bpm. RR interval 1523ms/39bpm

12. 30/01/2020 08:57:29



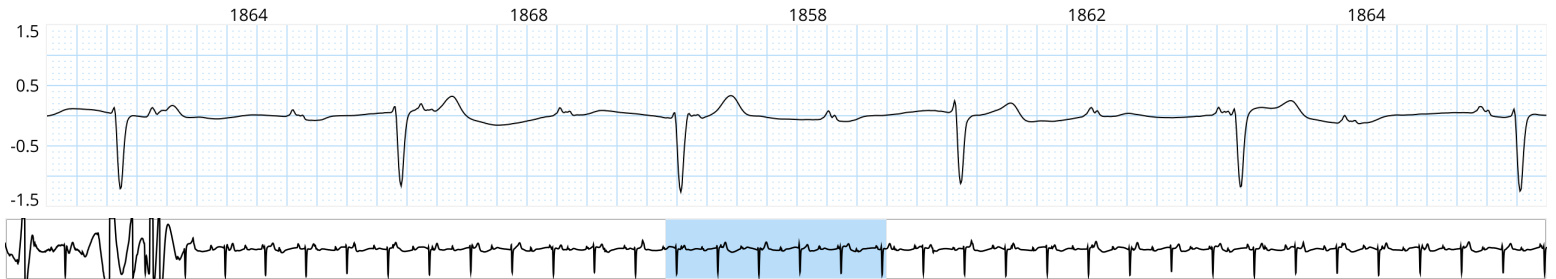
Comment: PP interval 523ms/115bpm. QRS duration 106ms

13. 30/01/2020 17:54:55



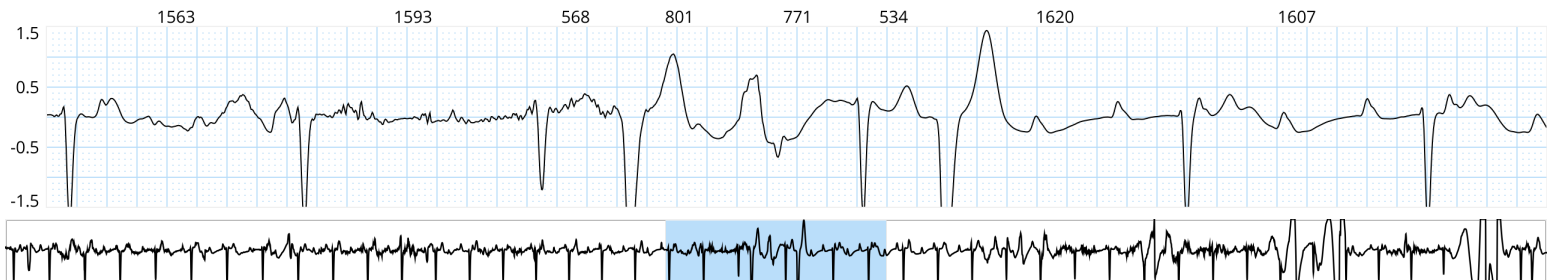
Comment: Irregular broad complex triplet

14. 31/01/2020 22:45:24



Comment: PP interval 859ms/70bpm. QRS duration 115ms

15. 01/02/2020 14:50:15



Comment: Isolated PVCs